

Roth's Spots

These are small red spots with a white centre seen in the back of the eye when the Optometrist or Doctor looks into your eye.

They occur in the part of the eye called the retina which is like the film in a camera. They usually occur not in the very centre of the vision but to one side and usually cause no visual problems. They are usually found as an incidental finding in an eye examination.

They consist of a small haemorrhage with a white centre.

Causes.

Unknown - Single ones are often seen and the cause never found

Anaemia

Thrombocytopenia (ie short of Platelets your clotting agent)

Rare causes include Endocarditis (Inflammation of the endocardium or lining of the heart) or Leukaemia.

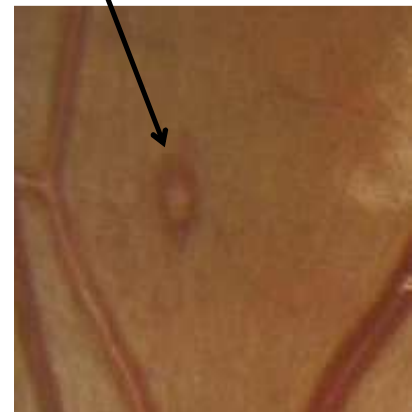
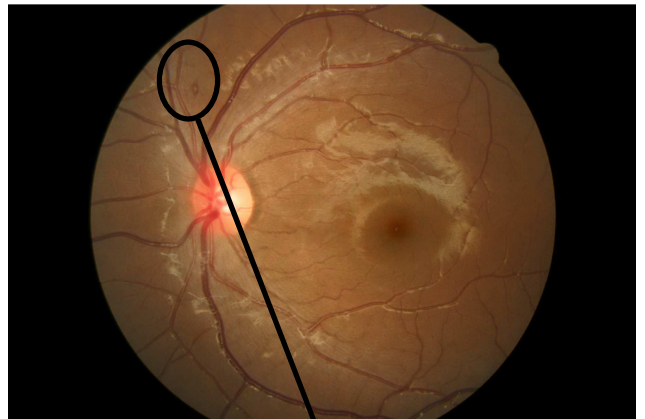
Thus if these are found a routine Medical examination including a Full blood count is recommended.

They usually disappear sometimes over a month or so, but sometimes longer.

This photograph illustrates how small they are and their typical location.

Mr. Nicholas Lee 2011

Lead Ophthalmic Clinician at The Hillingdon Hospital
Consultant Ophthalmologist at The Western Eye Hospital
Mobile 07956 263804. Fax 01895 835404



This document was created with Win2PDF available at <http://www.win2pdf.com>.
The unregistered version of Win2PDF is for evaluation or non-commercial use only.
This page will not be added after purchasing Win2PDF.